

# The Same Chemicals Induce Different Neurotoxicity When Administered in High Doses for Short Term or Low Doses for Long Term to Rats and Dogs†

SHINSUKE YOSHIMURA,\* KIYOSHI IMAI, YOSHIAKI SAITOH,  
HAJIME YAMAGUCHI, AND SACHI OHTAKI

*Department of Pathology, Hatano Research Institute,  
Food and Drug Safety Center, 729-5, Ochiai, Hadano,  
Kanagawa, 257, Japan*

Received June 21, 1991; Accepted August 9, 1991

## ABSTRACT

Dose- and term-dependent differences in the location and nature of brain lesions induced in rats and dogs by 2,5-hexanedione (2,5-HD), misonidazole, clioquinol, and acrylamide are reported. Subchronic neuropathies ("distal axonopathy") were induced by low-dose administration of these neurotoxicants and at high doses, lesions caused by acute or subacute neurotoxicity were found in the central nervous system (CNS). In rats, 2,5-HD induced extracellular edema, nerve cell degeneration, and axonal degeneration in the cerebellar and vestibular nuclei. Similar lesions were observed in misonidazole-treated dogs and clioquinol induced nerve cell degeneration in the hippocampus and malacia in the piriform lobes of these animals. In rats, acrylamide induced degeneration of Purkinje cells.

Although the mechanism(s) underlying the differential neurotoxicity of high and low doses of these neurotoxicants remains unclear, we suggest certain biochemical mechanisms, cytotoxic edema and excitotoxicity, as factors in the production of such lesions after high-dose treatment.

† This study was reported in part at the XIth International Congress of Neuropathology (I-P-38, Abstract p. 147), Kyoto, Japan, September 2-8, 1990.

\*Author to whom all correspondence and reprint requests should be addressed.

**Index Entries:** 2,5-Hexanedione; misonidazole; clioquinol; acrylamide; dose-related differential neurotoxicity; high-dose neurotoxicity; cerebellar nuclei; rat; beagle dog.

## INTRODUCTION

Accurate morphological studies, including the study of the ultrastructure of subcellular organelles, are essential for identifying the underlying pathological mechanisms or processes in any disorders. In the course of performing toxicity tests on several drugs, we sometimes encountered different neurological disorders and different neurotoxic changes induced by the administration of varied doses of the drugs to experimental animals.

Distal axonopathy is a hexacarbon neuropathy induced by 2,5-hexanedione (2,5-HD, a common metabolite of neurotoxic hexacarbons); it shows characteristic axonal swelling with accumulation of neurofilaments in the distal parts of the peripheral nerves and spinal cord (Spencer and Schaumburg, 1977a, 1977b; Yoshimura and Imai, 1986; Yoshimura et al., 1987). In previous studies (Yoshimura et al., 1988, 1990b), we found that high-dose treatment with 2,5-HD induced neurotoxicity that was characterized by edema and degeneration in the thalamus and cerebellar and vestibular nuclei. Therefore, we compared the nature and distribution of neurotoxic changes produced in experimental animals by a wide dosage range of 2,5-HD, misonidazole, clioquinol, and acrylamide.

In humans, the neurotoxicity of misonidazole (a hypoxic cell sensitizer) was an axonal-type neuropathy (Serman and Schaumburg, 1980; Urtasun et al., 1978; Wasserman et al., 1984); in rats (Griffin et al., 1979), mice (Chao et al., 1983), and dogs (Schärer, 1972), it was manifested as edematous changes in the brain. Clioquinol, 5-chloro-7-iodo-8-hydroxyquinoline, induces distal axonopathy resulting in subacute myelo-optic neuropathy (SMON) in humans; this was reproduced in dogs by prolonged administration of clioquinol (Tateishi and Otsuki, 1975; Tateishi et al., 1975; Yoshimura et al., 1984; Yoshimura and Imai, 1985, 1990) or its related compound, 5,7-dichloro-8-hydroxyquinoline (Yoshimura et al., 1989, 1990a; Yoshimura and Imai, 1990). Nerve cell degeneration in the hippocampus by high doses of quinoline has been reported in dogs (Lannek, 1974; Lannek and Jönsson, 1974). Acrylamide induces axonal swelling with accumulation of neurofilaments as a distal axonopathy (Schaumburg et al., 1974; Tilson, 1981; Yoshimura and Imai, 1986; Yoshimura et al., 1987), in addition, it induces degeneration of Purkinje cells (Cavanagh, 1982; O'Shaughnessy and Losos, 1986).

In the present study, we noted a relationship between the dose of neurotoxins and the characteristics of the induced pathological changes. After high-dose, short-term treatment with these chemicals, animals frequently died or became moribund with severe neurological signs; histo-

logical and electron microscopic studies revealed edematous, hemorrhagic, or necrotic foci in areas of the central nervous system (CNS). High-dose administration of 2,5-HD produced evidence suggestive of cytotoxic edema and excitotoxic mechanism(s). These findings, although they were based on morphologic examinations, suggest that in high doses, these chemicals may call into action similar neurotoxic mechanisms.

## METHODS

### *Animals and Treatment*

For each drug we designed experiments with varied dosage regimens; acute illness was induced by giving high dose(s), subchronic axonopathies by administering lower dose(s).

#### *2,5-Hexamedione*

Six-wk-old female Sprague-Dawley rats (total 24 rats, Crj:CD(SD) purchased from Charles River Japan Inc., Atsugi) were housed individually in wire-bottom metal cages and kept in a barrier-sustained animal room. 2,5-HD (Wako Pure Chemical Industries, Ltd.) was dissolved in distilled water in a vol of 5 mL/kg body wt. After 1 wk quarantine, they were divided into four groups: The first group ( $n = 10$ ) was administered orally with 700 mg/kg/d of 2,5-HD. The second group ( $n = 6$ ) was given 500 mg/kg/d. These rats became moribund with neurological signs after 3–10 d and were sacrificed by a perfusion fixation method (*see below*). The third group ( $n = 4$ ) was administered with 300 mg/kg/d of 2,5-HD, and the fourth group ( $n = 4$ ) was given distilled water and served as the control group. These rats were sacrificed on the 8th wk using the same perfusion method.

#### *Misonidazole*

Seven-mo-old female beagle dogs (total 11 animals, purchased from the CSK Laboratory Animal Institute) were housed individually in a wire-bottom metal cage and kept in a semibarrier-sustained animal room. Misonidazole (presented by Kayaku and Pola Corporation) was dissolved in phosphate-buffered saline. After 1-mo quarantine, the dogs were divided into four groups: In the two high-dose groups, they received 100 ( $n = 3$ ) or 80 mg/kg/d iv ( $n = 3$ ). Two other dogs were administered with 64 mg/kg/d; they were sacrificed by perfusion fixation when their neurological signs became severe (on the 2nd or 3rd wk). The three remaining dogs received 41 mg/kg/d of misonidazole iv for 6 wks and were sacrificed by the perfusion method.

#### *Clioquinol (Chinoform)*

In the high-dose group, three female beagle dogs were administered orally with 300 mg/kg of clioquinol two times a day (600 mg/kg/d). After

recovery from an episode of acute neurologic signs, they were sacrificed on the 5th wk, and the brain tissue was fixed by the immersion fixation method. In the low-dose group, two beagle dogs received orally an initial dose of 100 mg/kg/d for 1 wk, subsequently, the dose was gradually increased to 200 mg/kg/d for 1 wk and to 300 mg/kg/d for 2 wk. Thereafter, they were maintained at 400 mg/kg/d until sacrifice. The dogs in the low-dose group were sacrificed by the perfusion method 4 or 6 wk later when neurological signs became evident.

### *Acrylamide*

Six-wk-old female Sprague-Dawley rats (total 10 rats, Crj:CD(SD) purchased from Charles River Japan Inc., Atsugi) were maintained as described for the 2,5-HD experiment. Acrylamide was dissolved in distilled water in a vol of 5 mL/kg body wt. Six rats were given 50 mg/kg/d, po and sacrificed when their neurological signs became severe (on the 2nd or 3rd wk). Four rats were given 20 mg/kg/d of acrylamide; they were sacrificed on the 7th or 8th wk.

### *Perfusion Fixation and Pathological Examination*

Sodium pentobarbital-anesthetized animals were perfused through the ascending aorta (rats, 50 mL/min; dogs, 1000 mL/min) with phosphate-buffered saline followed by 0.1M phosphate-buffered-mixed-fixative of 2% paraformaldehyde plus 1.25% glutaraldehyde (pH 7.4). For light microscopical examination, tissues were embedded in paraffin and sections were stained with luxol fast blue-hematoxylin eosin (LFB-H-E). For electron microscopy, tissues were additionally fixed with 2% osmium tetroxide and embedded in epoxy resin. Semithin sections (about 1  $\mu$ m) were stained with toluidine blue, and ultrathin sections were stained with uranyl acetate followed by lead citrate.

## **RESULTS**

### *2,5-Hexanedione*

The body wt of rats given 500 mg/kg/d increased for 2 wk but decreased gradually after the 3rd wk. The weight of rats given 700 mg/kg/d decreased after 1 wk of administration (Fig. 1). Abnormal gait with swaying of the body was observed during the 2nd wk in animals given 700 mg/kg/d, and during the 3rd wk in those given 500 mg/kg/d. They were sacrificed on the 2nd or 3rd wk (700 mg/kg/d rats) and the 4th wk (500 mg/kg/d rats). The low-dose group (300 mg/kg/d) showed a relatively small weight gain, but no distinct signs of abnormal gait during the 7-wk experimental period.

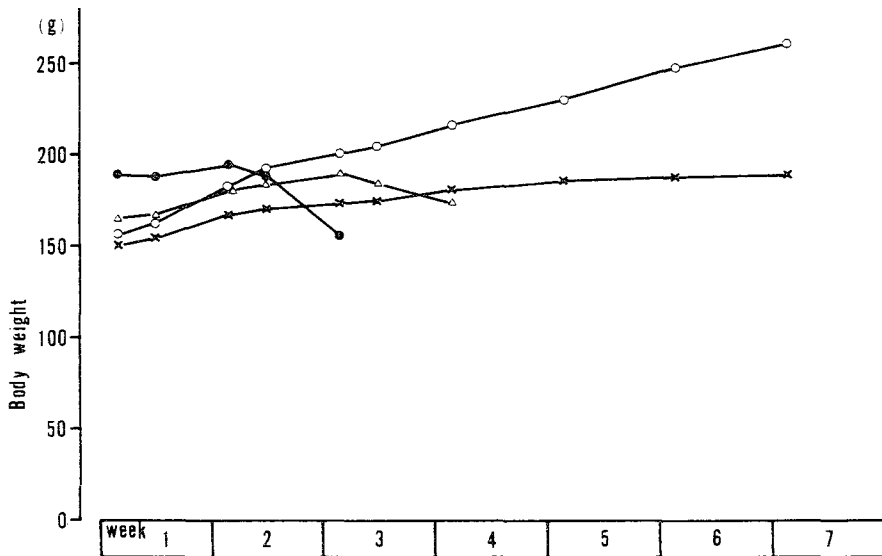


Fig. 1. Body wt change of rats treated with 2,5-hexanedione. ○: control; ×: 300 mg/kg/d; △: 500 mg/kg/d; ●: 700 mg/kg/d.

Histopathologically, the brains of rats given 500 or 700 mg/kg/d of 2,5-HD showed vacuolar change in the cerebellar and vestibular nuclei, and edema and necrosis in the thalamus (Table 1; Fig. 2B). In the cerebellar and vestibular nuclei of all 500 or 700 mg/kg/d rats, many large and small vacuoles were found (Fig. 3C and D). These large vacuoles sometimes contained a string-like structure, resembling an axon, stained with eosin (Fig. 3C and D, arrows). Degenerated nerve fibers showing myelin ovoids were also observed in these nuclei. Small foci of hemorrhage in these nuclei were detected in 1 of 6 rats dosed 500 mg/kg/d and 5 of 10 rats dosed 700 mg/kg/d (Table 1).

Ultrastructural examination of the cerebellar and vestibular nuclei of rats dosed 500 or 700 mg/kg/d showed that the periaxonal space of thick nerve fibers was occasionally dilated and contained intact or destroyed axoplasm (Fig. 4). There were wide spaces around nerve cells or between nerve fibers and foot processes of astrocytes, and the space contained a few membranous fragments. Many of the dendrites of nerve cells were swollen, and the endings also appeared to have undergone degenerative changes, containing many vesicles, swollen mitochondria, and fragments of organelles (Figs. 5, 6, and 7). Some of the nerve cells were destroyed, and their fragments or degenerated organelles were dispersed (Fig. 8). The perivascular space of the vessels in these nuclei was often dilated, and sometimes filled with erythrocytes (Fig. 9). Axonal degeneration was prominent in rats treated for 4 wk with 500 mg/kg/d 2,5-HD, and the axons

Table 1  
Histopathological Findings in Female Rats Treated Orally with 2,5-Hexanedione

Group	700 mg/kg							500 mg/kg							300 mg/kg			
	40 (15)	4 (15)	5 (15)	8 (15)	7 (16)	9 (16)	35 (16)	37 (16)	38 (22)	39 (22)	17 (29)	18 (26)	19 (29)	20 (29)	30 (29)	31 (29)	13 (53)	14 (53)
(Nervous tissues and findings)																		
(Cerebellar nucleus)																		
vacuolation	+	+	+	+	+	+	-	+	+	+	+	+	+	±	+		-	-
hemorrhage	-	-	-	+	+	-	-	-	-	-	-	-	-	-	-	+	-	-
myelin ovoid	+	+	-	+	±	-	+	+	+	±	+	+	±	±	+		-	-
degeneration of nerve cells	-	-	-	-	-	-	-	-	-	-	-	-	-	-	-		-	-
(Vestibular nucleus)																		
vacuolation	+	+	+	+	+	+	+	+	+	+	+	+	+	±	+		-	-
hemorrhage	-	-	-	-	+	+	+	+	-	-	-	-	-	-	-		-	-
myelin ovoid	+	+	±	±	+	-	+	+	+	±	+	+	±	±	+		-	-
degeneration of nerve cells	-	-	-	-	-	-	-	-	-	-	-	-	-	-	-		-	-
(Thalamus)																		
edema	±	+	+	+	-	-	-	±	+	+	+	+	+	±	±		-	-
degeneration of nerve cells	-	+	+	+	-	-	-	-	-	±	±	±	±	-	-		-	-
hemorrhage	-	-	-	-	-	-	-	-	+	-	-	+	+	-	-		-	-
(Cerebellar cortex)																		
degeneration of Purkinje cells	-	-	-	-	-	-	-	-	-	-	-	-	-	-	-		-	-
(Goll's tract in cervical cord)																		
axonal swelling	-	-	-	-	-	-	-	-	-	±	-	-	-	±	-		+	+
myelin ovoid	-	-	-	-	-	-	-	-	±	±	±	-	±	-	+		±	±
(Peripheral nerves)																		
axonal swelling	-	-	-	-	-	-	-	-	-	±	±	-	-	-	±		+	+
myelin ovoid	-	-	-	-	-	±	-	-	-	-	-	-	-	-	-		-	-

- : Negative; ± : Slight; + : Moderate; ++ : Marked.

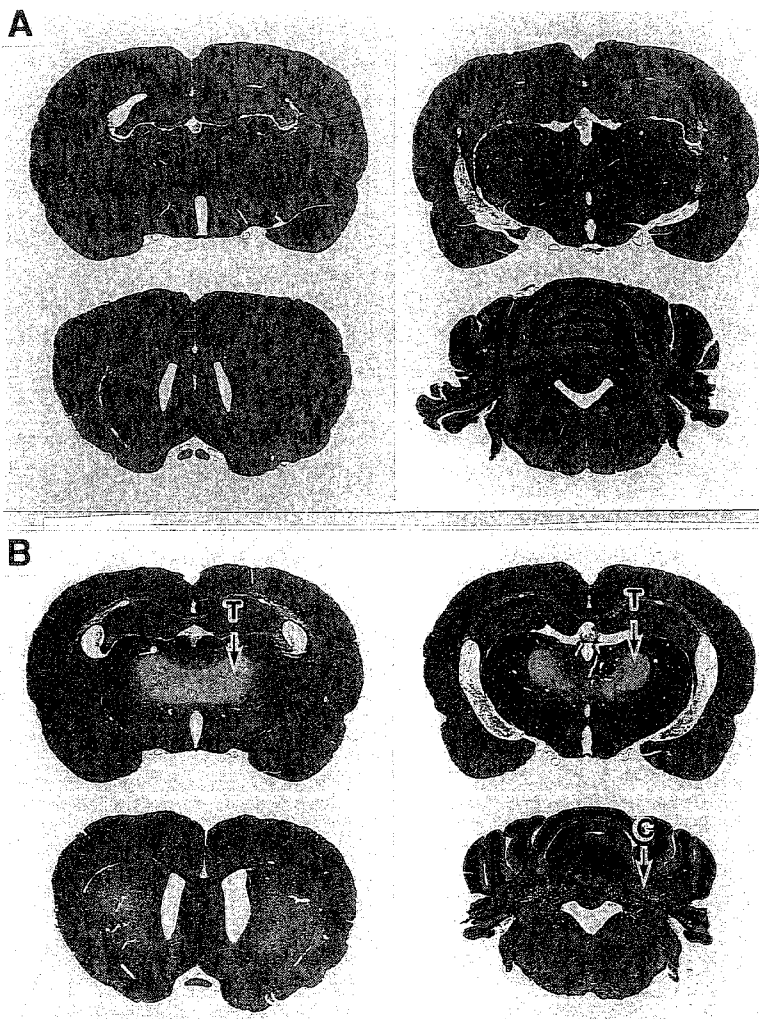


Fig. 2. 2,5-Hexanedione, 500 mg/kg/d, po. **A:** Brain slices of a control rat. **B:** Brain slices of a treated rat sacrificed 9 d after exhibiting neurological signs (4th wk). Edematous areas of the thalamus (T) and a vacuolated area of the cerebellar nuclei (C) are palely stained. Luxol fast blue-hematoxylin eosin stain.

frequently contained degenerated organelles or were densely stained (Fig. 10). Axonal swelling with accumulation of neurofilaments in the peripheral nerves was observed only rarely in the high-dose group.

In the thalamus, histopathologic examination revealed edematous and spongy change in all rats dosed with 500 mg/kg/d and in 6 of 10 rats dosed with 700 mg/kg/d; there was pale staining with LFB-H-E stain (Fig. 2B). Nerve cells in the edematous area of the thalamus were destroyed (Fig. 11C and D). Small foci of hemorrhage in the thalamus were observed

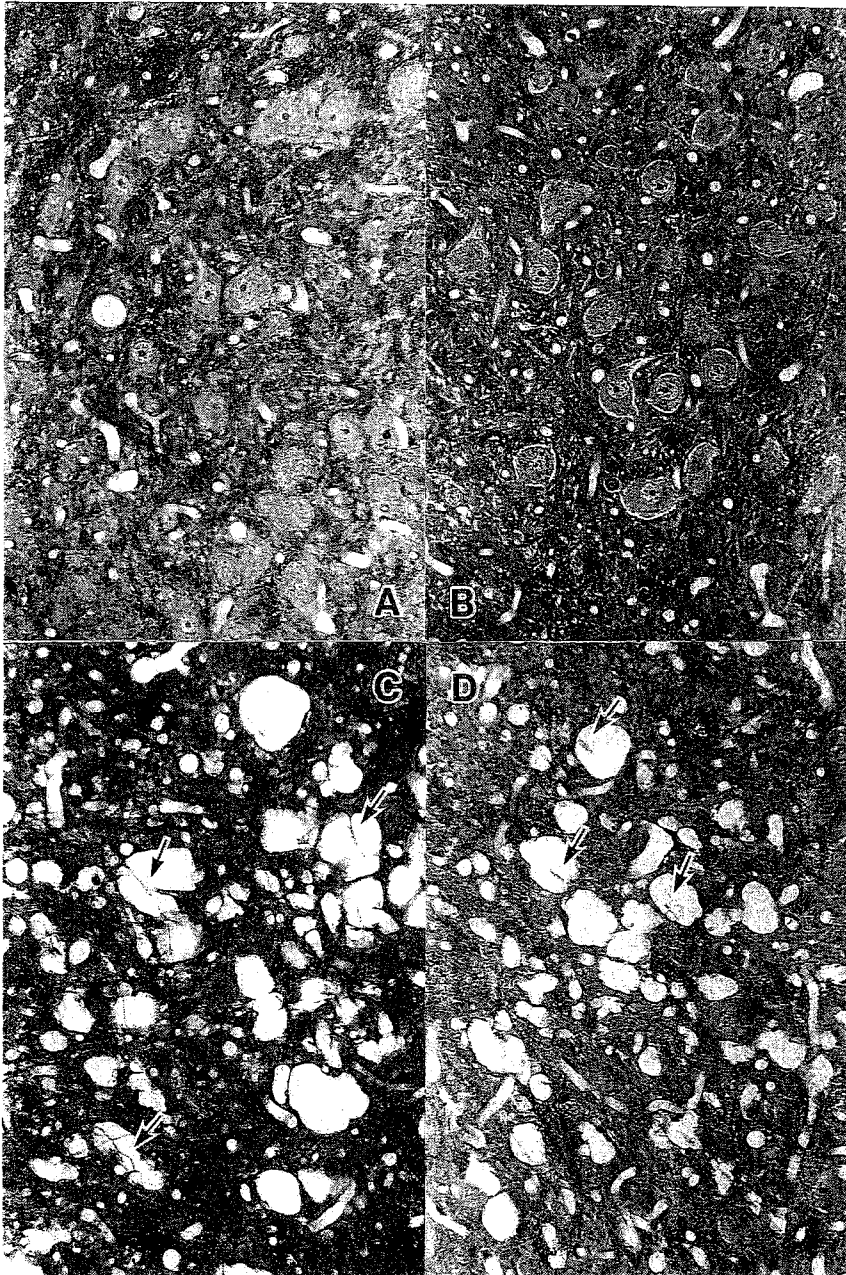


Fig. 3. 2,5-Hexanedione, 300 (B), 500 (C), or 700 mg/kg/d po. A: Cerebellar nucleus of a control rat. Cerebellar nucleus of a rat treated with B: 300 mg/kg/d and sacrificed on the 8th wk, C: 500 mg/kg/d and sacrificed 9 d after onset of neurological signs during the 4th wk. D: 700 mg/kg/d and sacrificed 6 d after the onset of signs on the 3rd wk. Large and small vacuoles were found in the cerebellar nucleus of rats treated with 500 or 700 mg/kg/d. These large vacuoles sometimes contained a string-like structure (an axon) stained with eosin (arrows). Luxol fast blue-hematoxylin eosin stain.



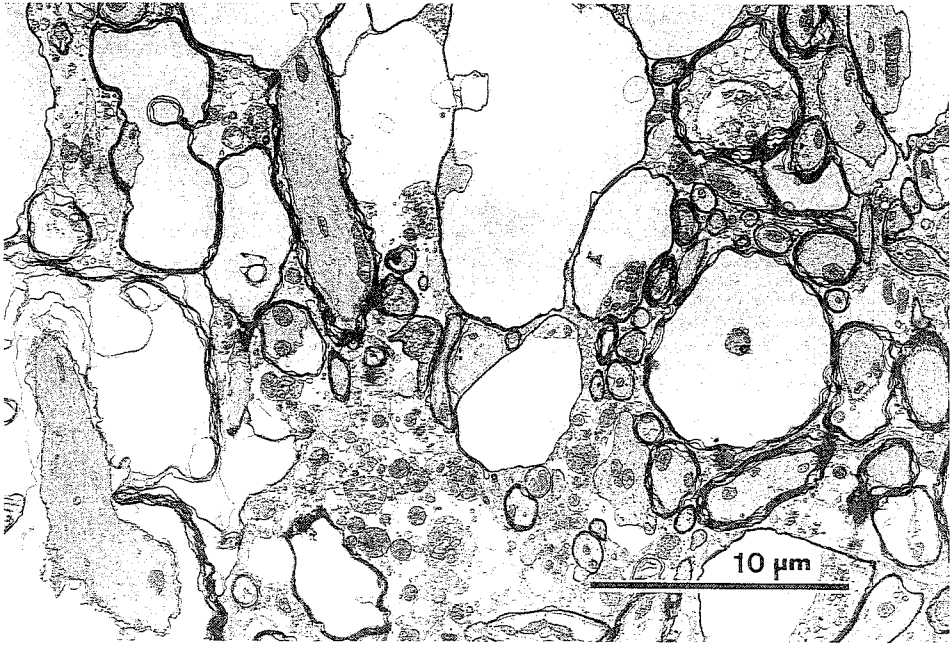


Fig. 4. 2,5-Hexanedione, 700 mg/kg/d, po. Cerebellar nucleus of a rat sacrificed 6 d after onset of neurological signs on the 3rd wk. The periaxonal space is extensively dilated. Thin epoxy section stained with uranyl acetate and lead citrate.

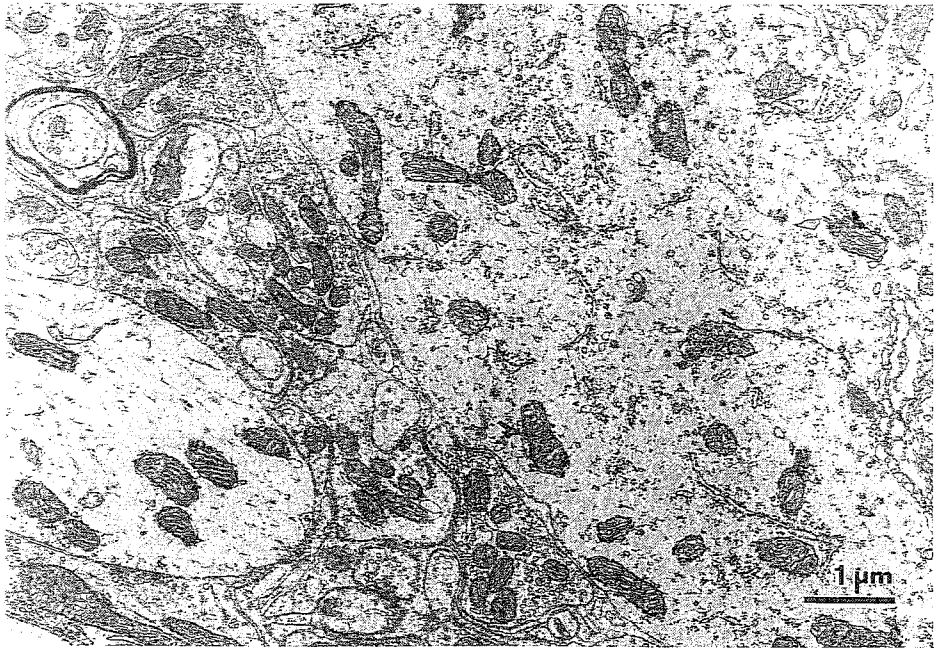


Fig. 5. Cerebellar nucleus of a control rat. Thin epoxy section stained with uranyl acetate and lead citrate.

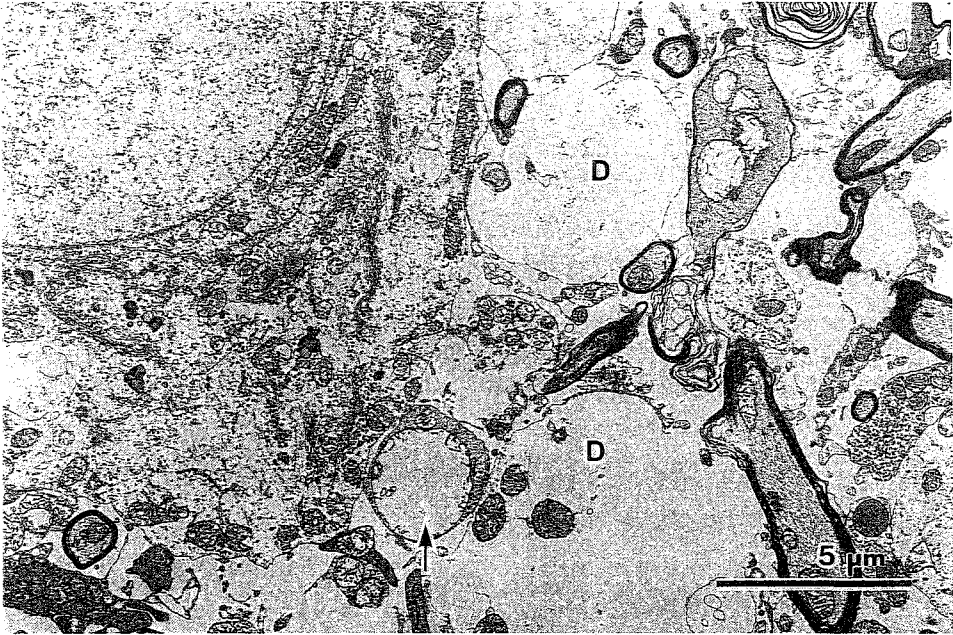


Fig. 6. 2,5-Hexanedione, 700 mg/kg/d, po. Extracellular edema in the cerebellar nucleus of a rat sacrificed on the 3rd wk when neurological signs became severe 6 d after onset. The extracellular space is dilated and contains membranous material and degenerated organelles, including features suggesting swelling of dendrites (D). Some nerve endings exhibit degenerated mitochondria (arrow). Thin epoxy section stained with uranyl acetate and lead citrate.

in 2 of 6 rats dosed with 500 mg/kg/d and in 1 of 10 rats dosed with 700 mg/kg/d (Table 1).

Histopathological examination of the low-dose group (300 mg/kg/d) revealed no edematous changes in the brain (Figs. 3B and 11B). The characteristic change in the low-dose group was axonal swelling with accumulation of neurofilaments in the *fasciculus gracilis* of the cervical cord and peripheral nerve fibers (Fig. 12). Axonal swelling in the low-dose, prolonged administration group was more prominent than in the high-dose group.

### Misonidazole

After 1 or 2 wks of treatment with 64, 80, or 100 mg/kg/d of misonidazole, all eight dogs developed severe neurological signs, such as excess salivation, nystagmus, and disequilibrium of the body, and were sacrificed 1-7 d after onset. In the cerebellar and vestibular nuclei, extracellular edema, dilatation of the periaxonal space, axonal degeneration, swelling of dendrites, and degeneration of nerve endings were noted ultrastructurally in all five dogs dosed 64 or 100 mg/kg/d (Figs. 13 and 14). These changes resembled the lesions seen in rats treated with high doses (700, 500 mg/kg/d) of 2,5-HD. In the entopeduncular nuclei of the dogs, edematous changes were observed in paraffin sections stained with LFB-H-E

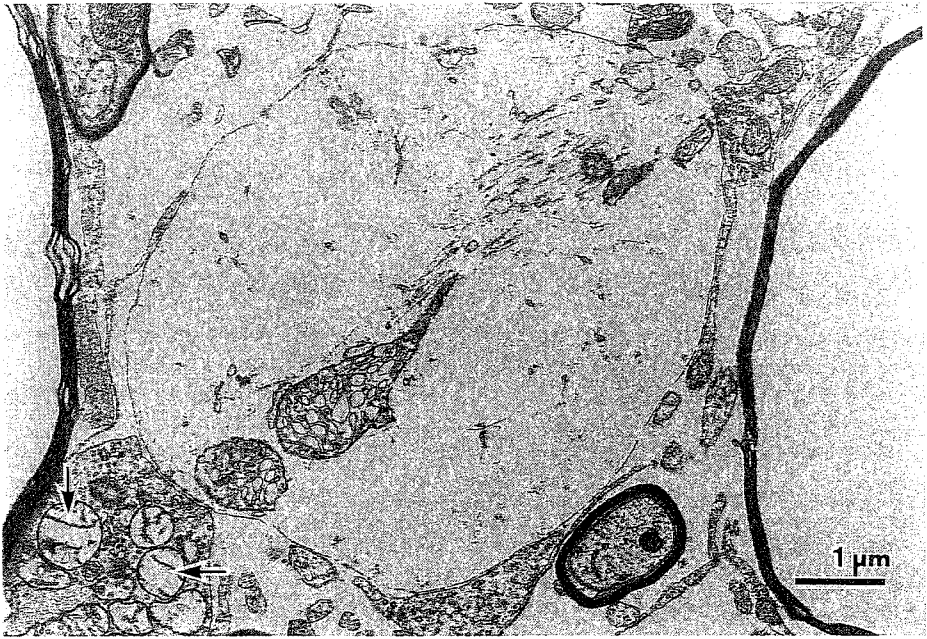

Fig. 7. 2,5-Hexanedione, 700 mg/kg/d, po. Cerebellar nucleus of a rat sacrificed on the 3rd wk when neurological signs became severe 6 d after onset. Dendrites are swollen and exhibit degenerated mitochondria. Mitochondria in a nerve ending are also degenerated (arrows). Thin epoxy section stained with uranyl acetate and lead citrate.




Fig. 8. 2,5-Hexanedione, 700 mg/kg/d, po. Cerebellar nucleus of a rat sacrificed on the 3rd wk. Note the destroyed nerve cell (A); fragments of the nucleus (N) and organella are dispersed. Thin epoxy section stained with uranyl acetate and lead citrate.

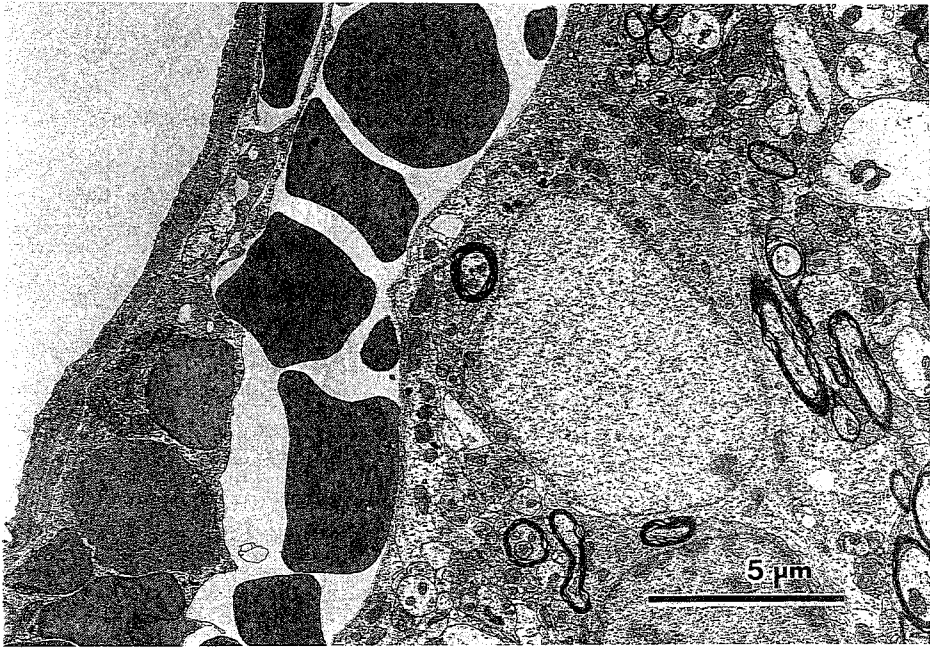


Fig. 9. 2,5-Hexanedione, 700 mg/kg/d, po. Hemorrhage into the perivascular space in the vestibular nucleus of a rat sacrificed on the 3rd wk, 8 d after onset of neurological signs. Thin epoxy section stained with uranyl acetate and lead citrate.

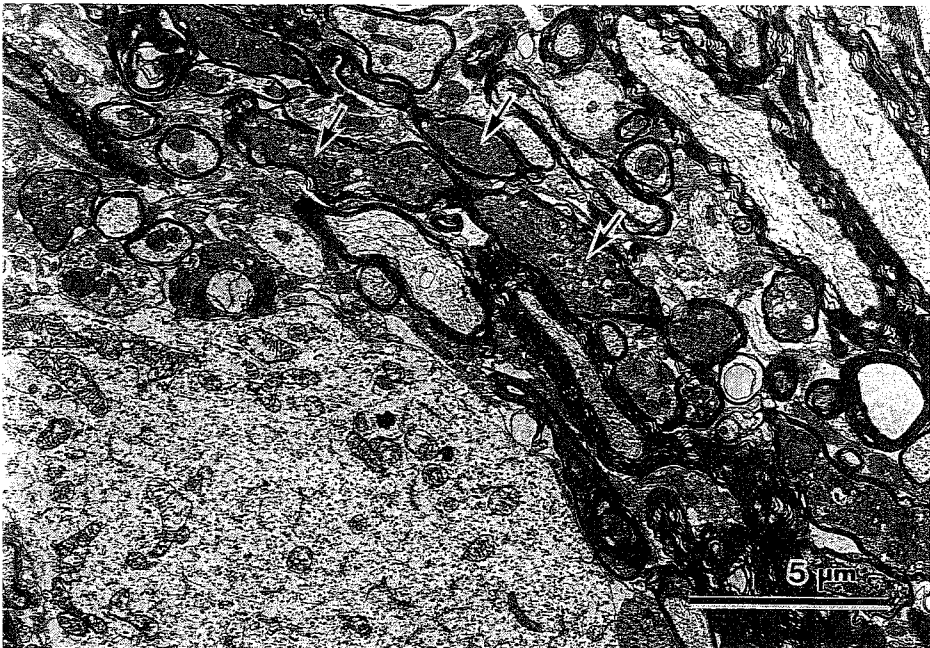


Fig. 10. 2,5-Hexanedione, 500 mg/kg/d, po. Cerebellar nucleus of a rat sacrificed on the 4th wk, 12 d after onset of neurological signs. Many axons are degenerated, and densely stained organelles are accumulated in these axons (arrows). Thin epoxy section stained with uranyl acetate and lead citrate.



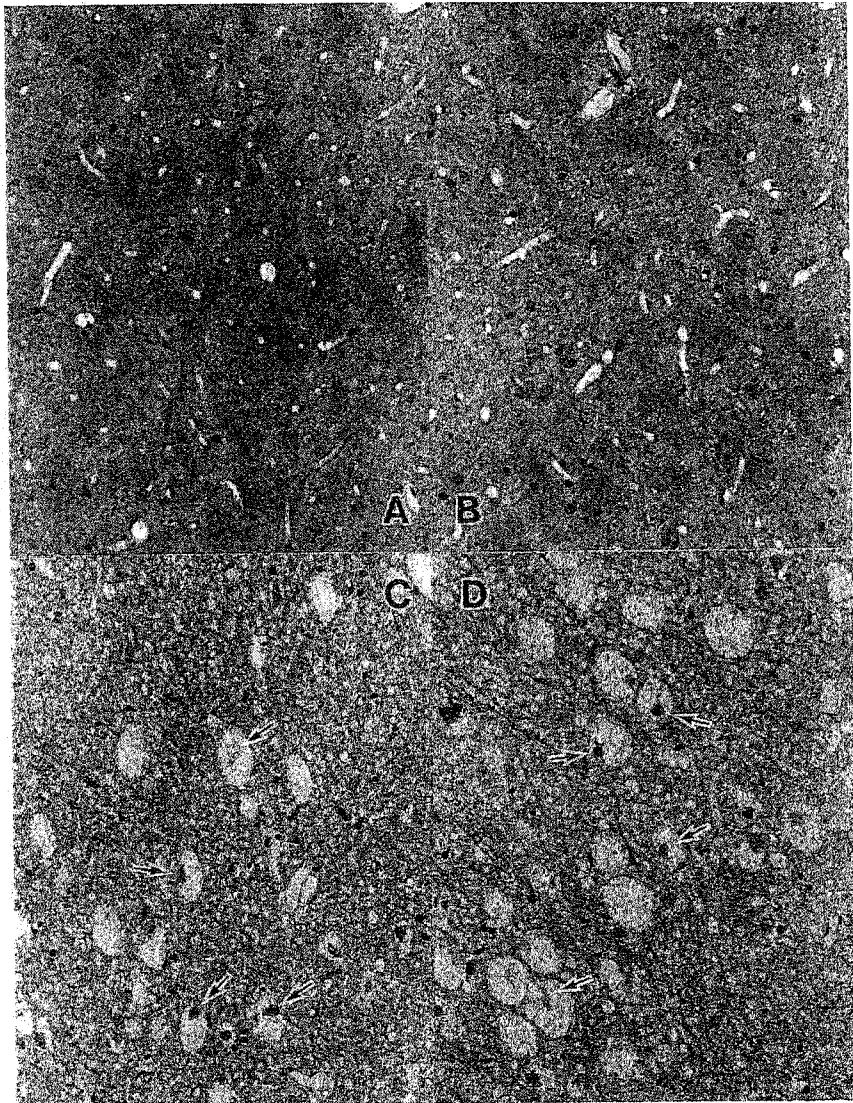


Fig. 11. 2,5-Hexanedione, 300 (B), 500 (C), or 700 mg/kg/d, po. Thalamus of a control rat (A) and a rat treated with 300 mg/kg/d and sacrificed on the 8th wk (B). The nerve cells in the edematous area of the thalamus were destroyed (arrows) in rats treated with 500 mg/kg/d (C) or 700 mg/kg/d (D). Luxol fast blue-hematoxylin eosin stain.

(Fig. 15B) and in ultrathin sections of dogs receiving 80 or 100 mg/kg/d misonidazole. Sporadic hemorrhagic foci were noted in the entopeduncular, cerebellar, and vestibular nuclei, and in the cerebellar cortex.

Moreover, the Purkinje cells of two dogs each in the groups receiving 64 and 80 mg/kg/d and one dog in the group receiving 100 mg/kg/d exhibited marked swelling and degeneration (Fig. 16B). In the molecular layer of the cerebellar cortex many vacuoles were observed, and the dendrites of Purkinje cells contained degenerated organelles (Fig. 17).

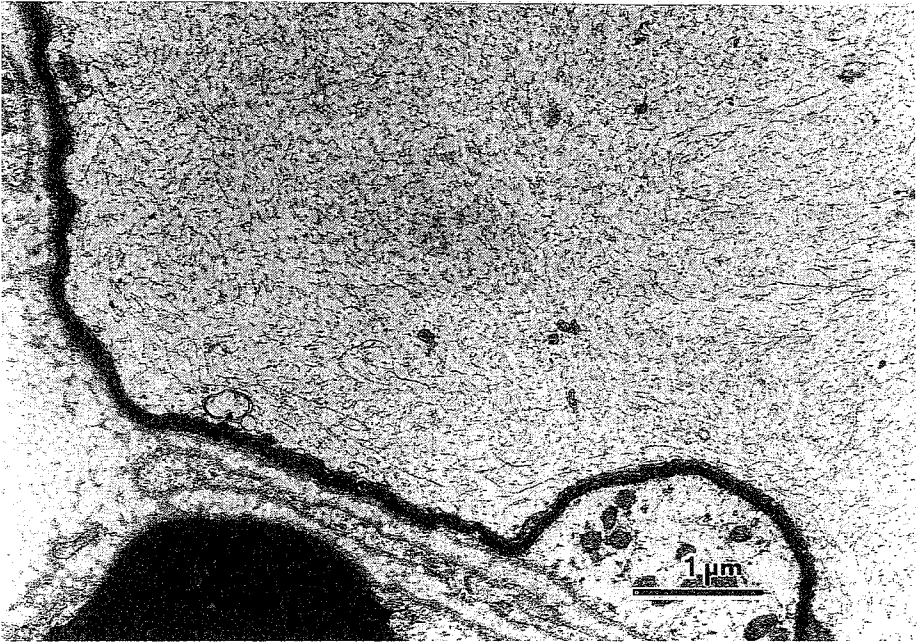


Fig. 12. 2,5-Hexanedione, 300 mg/kg/d, po. Tibial nerve of a rat sacrificed on the 8th wk. A nerve fiber has an abnormally thin myelin sheath; the axon is swollen and contains numerous neurofilaments with disorganized arrangement. Thin epoxy section stained with uranyl acetate and lead citrate.

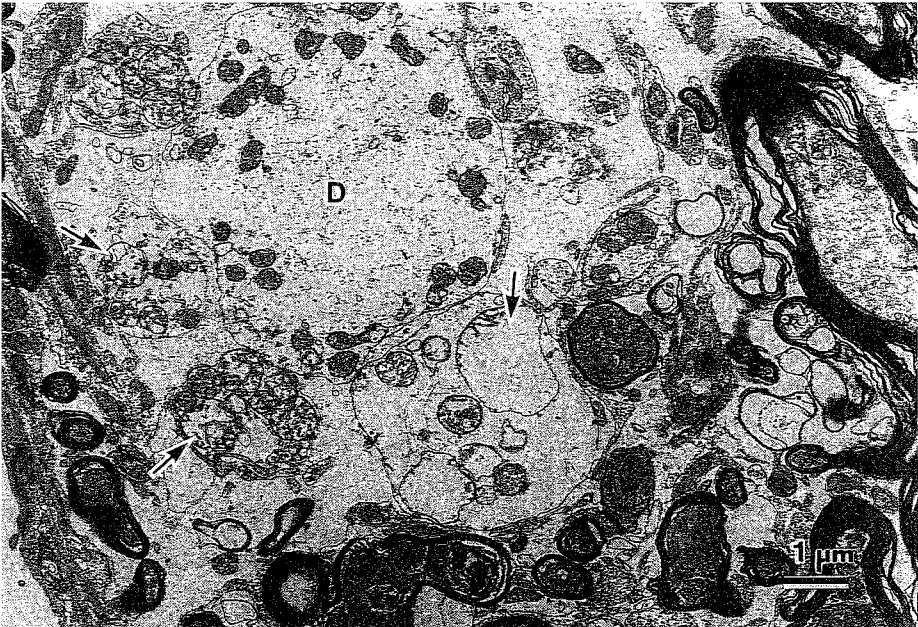


Fig. 13. Misonidazole, 100 mg/kg/d, iv. Cerebellar nucleus of a beagle sacrificed on the 2nd wk, 7 d after the onset of neurological signs. The extracellular space is dilated and contains cellular fragments and flocculent material. Note the swollen dendrite of a nerve cell (D); the nerve endings are also swollen and contain degenerated mitochondria (arrows). Many axons are degenerated and intensely stained. Thin epoxy section stained with uranyl acetate and lead citrate.

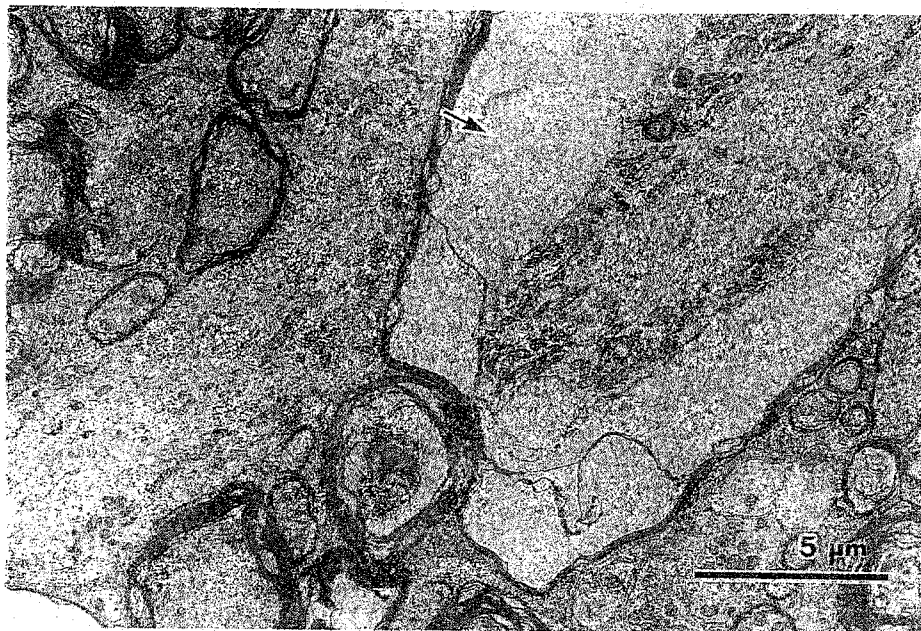


Fig. 14. Misonidazole, 80 mg/kg/d, iv. Cerebellar nucleus of a beagle dog sacrificed on the 2nd wk, 1 d after onset of neurological signs. The periaxonal space is extensively dilated (arrow). Thin epoxy section stained with uranyl acetate and lead citrate.

In the group dosed with 41 mg/kg/d, the edematous changes in the cerebellar and vestibular nuclei were very slight and the Purkinje cells were intact (Fig. 16A). No distinct change was detected in the nerve fibers of the spinal cord or in the peripheral nerves of all 11 misonidazole-treated dogs.

### **Clioquinol**

All three dogs receiving 600 mg/kg/d clioquinol developed acute neurological signs on the 3rd or 4th d, such as excess salivation, hypersensitivity, and convulsion. After the dosage was decreased for a few days to allow recovery from the signs of acute intoxication, high-dose treatment was resumed, and the dogs began to exhibit abnormal gait on the 3rd or 4th wk; they were sacrificed on the 5th wk. In 2 of the 3 dogs, the hippocampal nerve cells were selectively degenerated or had disappeared, and there were many glial cells around them (Fig. 18B). In all dogs, a wide area extending from the piriform lobe to the olfactory tract was necrotic, forming cysts (Figs. 19B and 20).

Dogs in the ascending dose group developed abnormal gait after 3 or 4 wk when the dose reached 300 or 400 mg/kg/d, and after a few weeks, when the neurological signs became severe, their nervous tissues were fixed by the perfusion method. Pathological lesions in the central nervous tissue of these dogs were characterized by axonal degeneration of nerve fibers in the optic tract, *fasciculus gracilis* (Fig. 21), spinocerebellar tract in the cervical cord, and corticospinal tract in the lumbar cord.

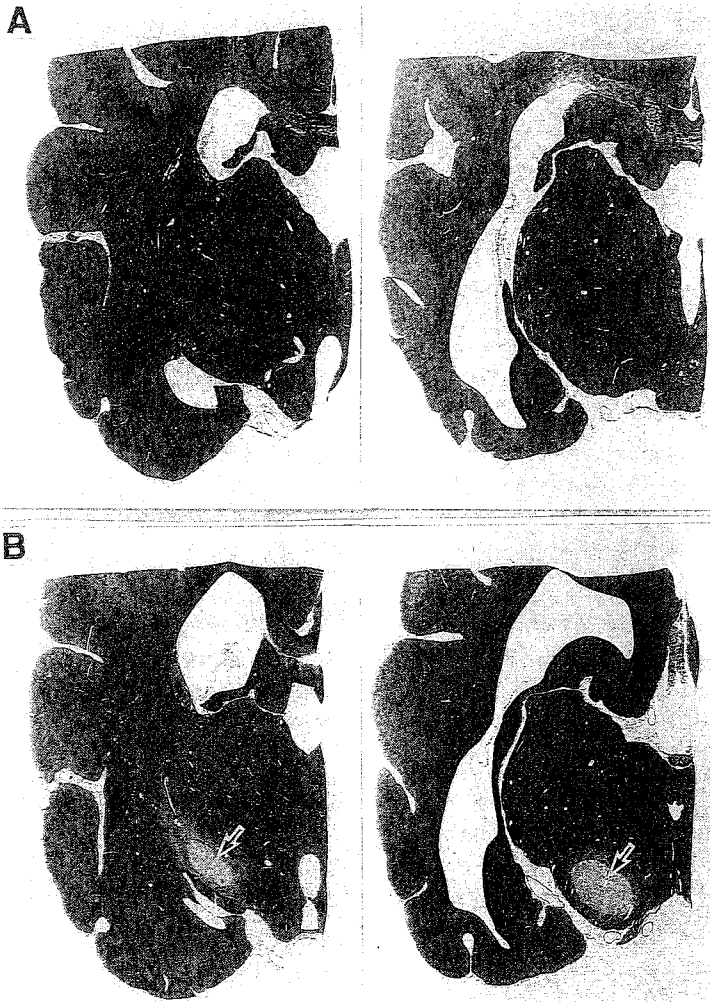


Fig. 15. Misonidazole, iv. **A:** Brain of a beagle dog administered with 41 mg/kg/d for 6 wk. **B:** Partial edema (arrows) in the brain of a beagle dog administered with 100 mg/kg/d and sacrificed on the 2nd wk, 7 d after onset of neurological signs. The entopeduncular nucleus is palely stained owing to *in situ* edema. Luxol fast blue-hematoxylin eosin stain.

### Acrylamide

Histopathologic examination of rats treated with 50 mg/kg/d and sacrificed on the 2nd or 3rd wk showed vacuolar changes in the molecular layer of the cerebellar cortex and condensation of Purkinje cells (Fig. 22B). In addition, there was distal axonopathy restricted to the long tracts of the spinal cord and peripheral nerves. Ultrastructurally, the degenerated



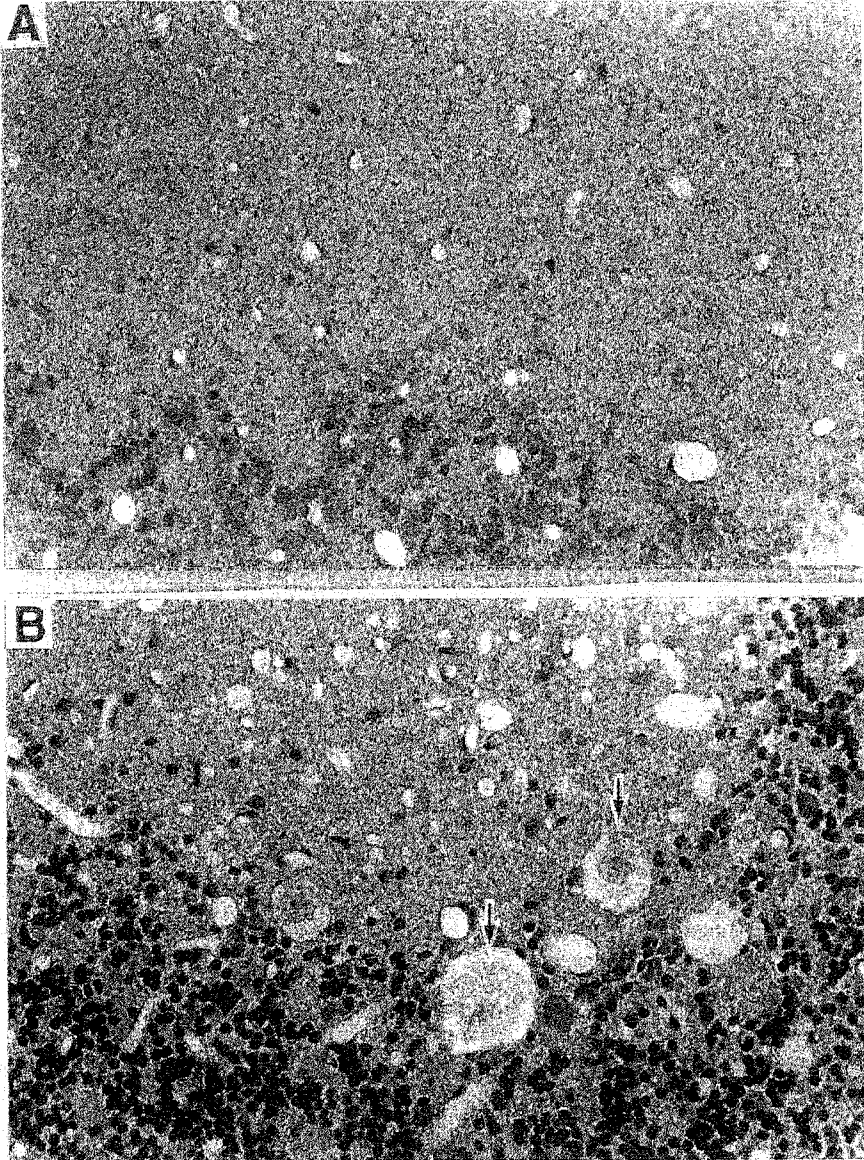


Fig. 16. Misonidazole, iv. **A:** Cerebellar cortex of a beagle dog administered with 41 mg/kg/d for 6 wk. Purkinje cells are intact. **B:** Cerebellar cortex of a beagle dog administered with 100 mg/kg/d and sacrificed 7 d after the onset of neurological signs, on the 2nd wk. Purkinje cells are swollen and palely stained (arrows). There are many vacuoles in the molecular layer. Hematoxylin eosin stain. x280

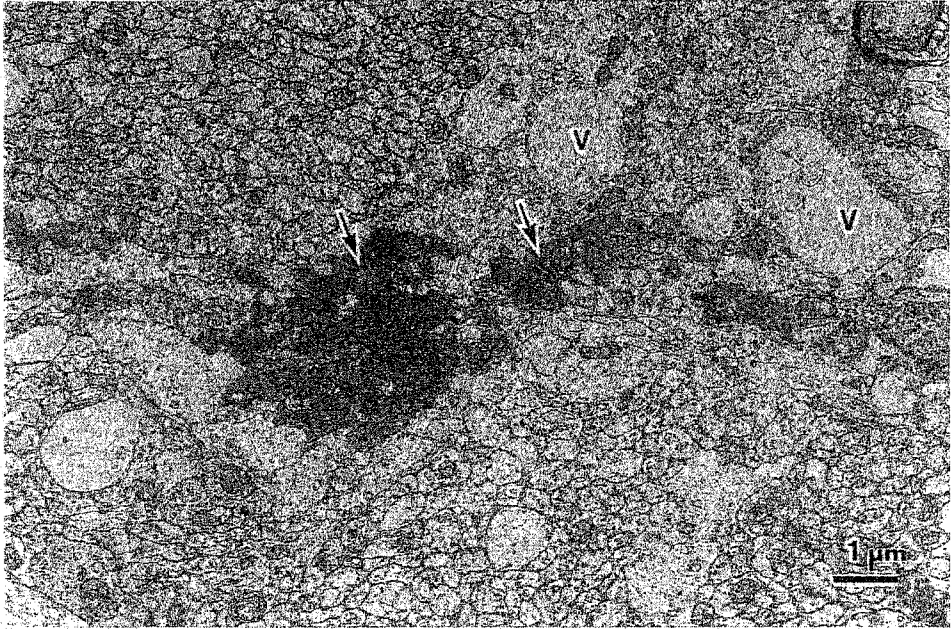


Fig. 17. Misonidazole, 80 mg/kg/d, iv. Molecular layer in cerebellar cortex of a beagle dog sacrificed 6 d after the onset of neurological signs, on the 3rd wk. The dendrite of a Purkinje cell contains densely stained materials (arrows) and vacuoles (V). Thin epoxy section stained with uranyl acetate and lead citrate.

Purkinje cells manifested accumulation of densely stained, degenerated organelles in the cytoplasm and dendrites (Fig. 23). Treatment with 20 mg/kg/d for 7 or 8 wks induced a typical distal axonopathy, i.e., accumulation of neurofilaments in the axoplasm of the distal part of the central and peripheral nerve fibers.

## DISCUSSION

We observed dose-dependent, different neurotoxicity of the same chemical in rats treated with 2,5-HD or acrylamide and in dogs treated with clioquinol. Low-dose and subchronic treatment produced distal axonopathy either in CNS (clioquinol), or in both CNS and peripheral nervous system (PNS) (2,5-HD and acrylamide). High-dose, short-term treatment, on the other hand, induced edematous and/or degenerative changes in particular regions of the CNS, such as the hippocampus and piriform lobe (dogs, clioquinol) and thalamus (rats, 2,5-HD), the entopeduncular nuclei (dogs, misonidazole), cerebellar and vestibular nuclei (rats, 2,5-HD and dogs, misonidazole), and cerebellar cortex and Purkinje

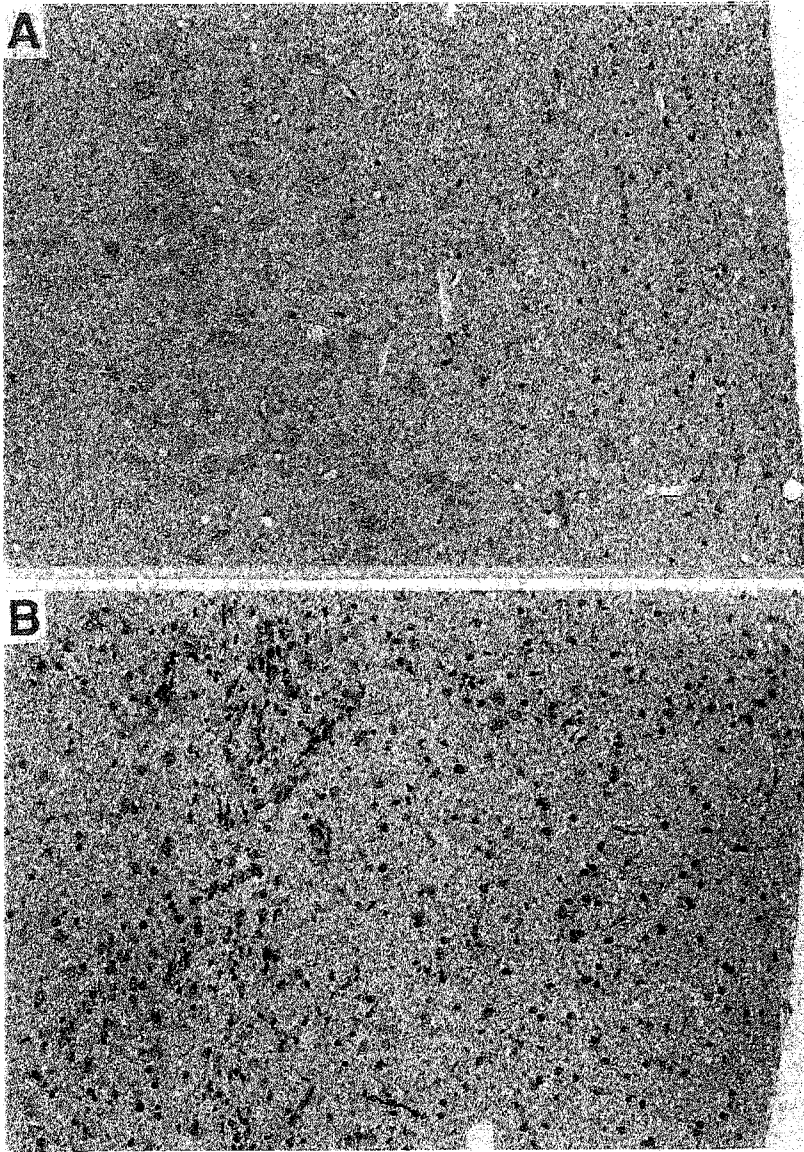


Fig. 18. Clioquinol, po. **A:** Hippocampus of a beagle dog treated with increasing doses. The nerve cells are intact. **B:** Hippocampus of a beagle dog treated with 600 mg/kg/d. The nerve cells are destroyed or have disappeared, and there are many glial cells. Hematoxylin eosin stain. x175

cells (dogs, misonidazole and rats, acrylamide). That is, high doses of 2,5-HD induced lesions in the cerebellar nuclei of rats, but not in Purkinje cells. Acrylamide induced degenerative changes of rat Purkinje cells, but not in rat cerebellar nuclei. In dogs, both the Purkinje cells and cerebellar nuclei were affected by misonidazole intoxication. Since the major nerve fibers distributing to the cerebellar nucleus derive from Purkinje cells, our

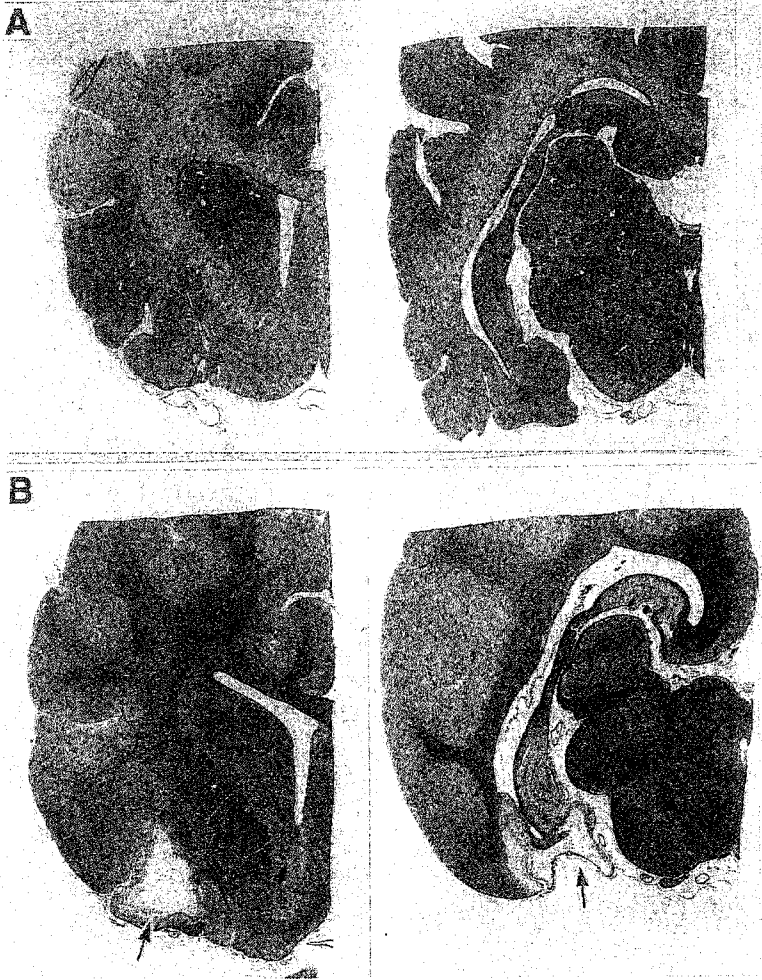


Fig. 19. Clioquinol, po. **A:** Brain slices of a beagle dog treated with gradually increasing doses. **B:** Brain slices of a beagle dog treated with 600 mg/kg/d. The dog recovered from acute intoxication, and was sacrificed after 5 wk of treatment. A wide area from the piriform lobe to the olfactory tract was necrotic and formed large cysts (arrows). Luxol fast blue-hematoxylin eosin stain.

observations suggest that the neurons may be more vulnerable to damage by misonidazole and acrylamide.

We found that high-dose, short-term treatment with the different drugs used resulted in destructive changes in the CNS, indicative of brain neurotoxicity. The question arises regarding why the same drug can induce different, dose-dependent neurotoxicity. It is possible that different mechanisms are involved, although there may be some overlapping.

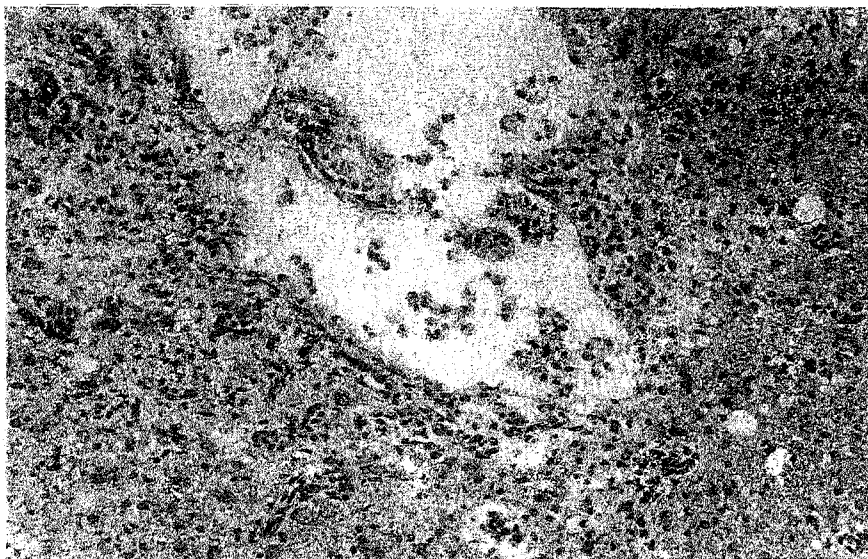


Fig. 20. Clioquinol, 600 mg/kg/d, po. Piriform lobe of the brain of a beagle dog that was allowed to recover from acute intoxication, and then sacrificed after 5 wk of treatment. There is a wide necrotic area with many phagocytes. Luxol fast blue-hematoxylin eosin stain.  $\times 175$

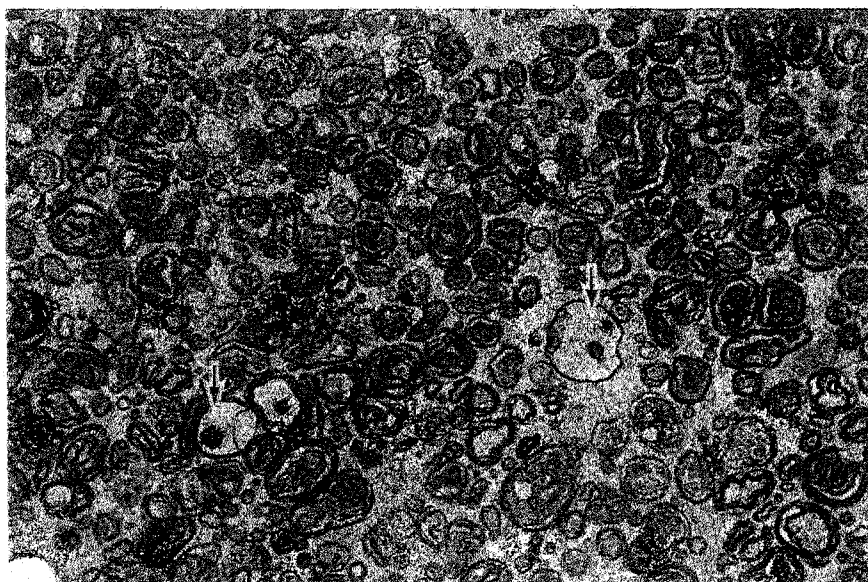


Fig. 21. Clioquinol, 100 mg/kg/d gradually increasing to 400 mg/kg/d, po. *Fasciculus gracilis* of a beagle dog. Many of the degenerated axons show myelin ovoids. Macrophages are infiltrated into degenerated nerve fibers (arrows). Semithin section stained with toluidine blue.  $\times 700$



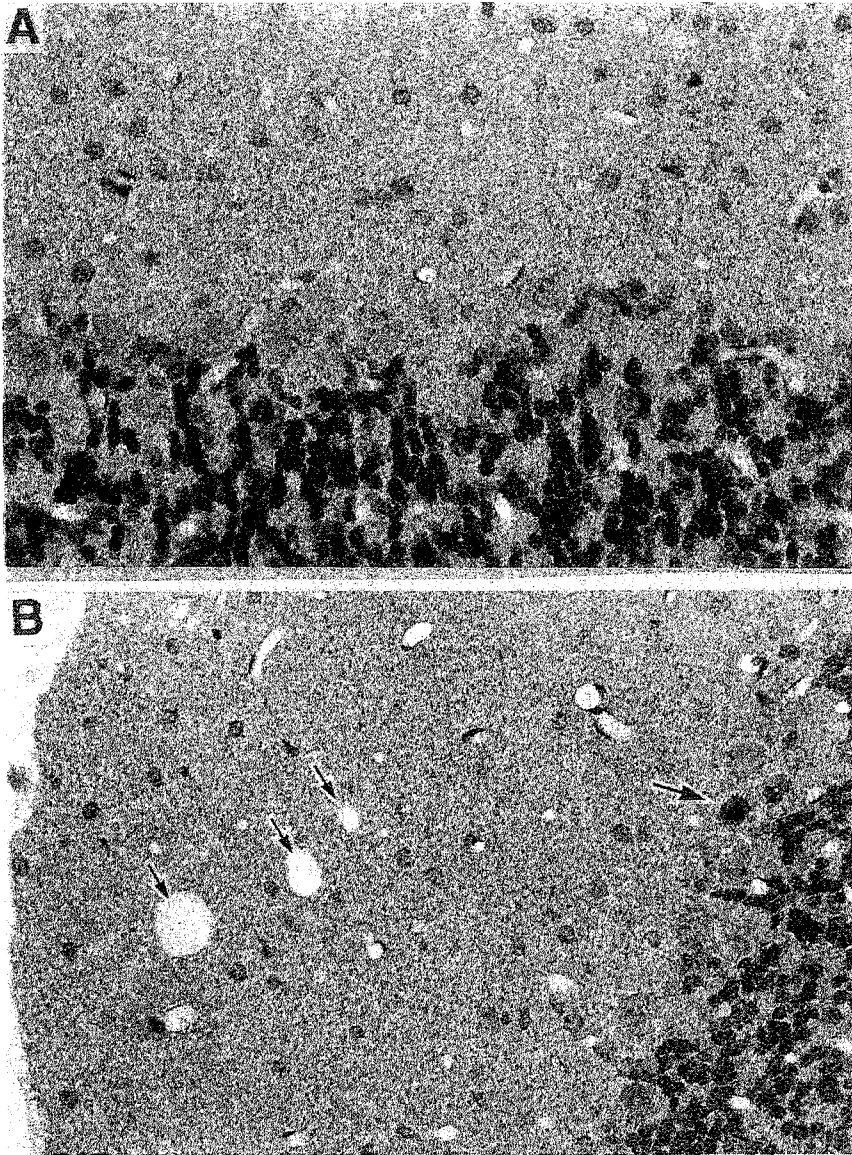


Fig. 22. Acrylamide, 20 mg/kg/d (A) or 50 mg/kg/d (B), po. A: Cerebellar cortex of a rat treated with 20 mg/kg and sacrificed on the 7th wk. Purkinje cells are intact. B: Cerebellar cortex of a rat treated with 50 mg/kg and sacrificed on the 2nd wk. A single Purkinje cell is degenerated and stained densely (large arrow). There are vacuoles in the molecular layer (small arrows). Hematoxylin eosin stain. A: x350, B: x280

Neurotoxins or neurotoxicants produce different effects depending on the specific molecular composition of the affected nervous tissues disturbing nerve function at that site by chemical binding or action. If distal axonopathies occur in accordance with this hypothesis, different nerve elements may have different vulnerable sites for each chemical. For other neurotoxicity, brain edema or neuronal damage induced by high doses of these drugs, different mechanism(s) might be responsible.

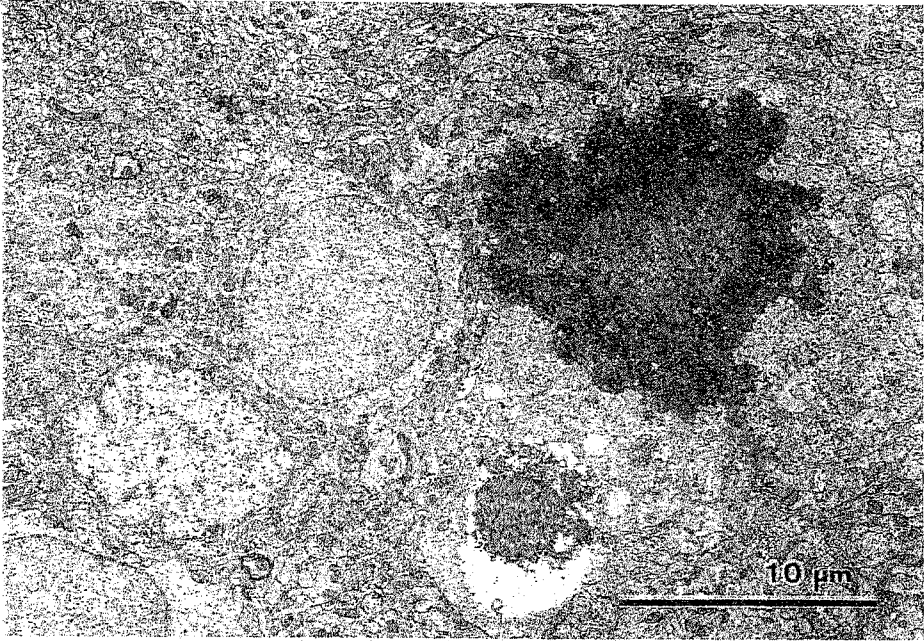


Fig. 23. Acrylamide, 50 mg/kg/d, po. Purkinje cell in the cerebellar cortex of a rat treated with 50 mg/kg/d and sacrificed on the 2nd wk. Degenerated and densely stained organelles are accumulated in the cytoplasm of the Purkinje cell. Thin epoxy section stained with uranyl acetate and lead citrate.

The localization of the brain edema and the destructive changes induced by high-doses of 2,5-HD and misonidazole may point to cytotoxic edema owing to disturbances of osmo- and ion homeostasis, rather than simple (nontoxic) vasogenic edema, which mostly occurs in the white matter of the brain (Klatzo, 1967, 1987). The primary cytotoxic edema, however, may be associated with vasogenic edema as a result of cytotoxic damage to the astrocytes that are essential for the blood-brain barrier, and especially susceptible to disturbances in cell osmoregulation (Klatzo, 1967). The observed brain edema thus could be of a mixed type, and the cytotoxic changes may eventually induce secondary active mediators.

Excitotoxicity is thought to be the most obvious mechanism underlying neuronal destruction. The neuron-destroying process by excitotoxins is acute, and destroyed neurons are phagocytized and disappear within only a few hours (Olney, 1980), so that it is difficult to observe this process. Our findings were obtained 3–7 d after the onset of neurological signs induced by high-dose 2,5-HD or misonidazole, so they may have been at the end-stage of excitotoxic neuronal damage. As shown in Figs. 6, 7, 8, and 13, however, swelling and destruction of nerve cells seemed to first occur in the dendrites. This is strongly suggestive of a stage of excitotoxic neuronal damage, which has been termed a "dendrosomatotoxic," but "presynaptic axon-sparing" type of cytopathologic reaction (Olney, 1980).

Nerve loss in the hippocampus and malacia in the piriform lobe of dogs treated with larger doses of clioquinol is suggestive of a later consequence of neuronal damage. Although hippocampal lesions have been postulated to be of ischemic nature (Krinke et al., 1978), Olney (1989) suggested that they may be involved in an endogenous excitotoxic action. Compound neurotoxicity, nerve injury in CNS and distal axonopathy induced by acrylamide, may be brought about by intermediate doses.

Our morphological study revealed that the same chemicals induce different, dose-dependent neurotoxicity. Although these neurotoxicants regularly induce toxic changes primarily in the axons, at high doses, they may attack the dendrosomal portion of neurons in the CNS regions that are vulnerable to known excitotoxins. For this, cytotoxic edema-induced secondary mediator(s) may be required. Whether the nature and site-specificity of the observed lesions is indicative of more specified mechanism(s) for each chemical, requires further study.

## ACKNOWLEDGMENTS

This work was supported in part by the SMON Research Commission of the Ministry of Health and Welfare, Japan. We thank Kayaku and Pola Corporation for a supply of misonidazole.

## REFERENCES

- Cavanagh J. B. (1982) The pathokinetics of acrylamide intoxication: A reassessment of the problem. *Neuropathol. Appl. Neurobiol.* **8**, 315-336.
- Chao C. F., Subjeck J. R., and Johnson R. J. (1983) Behavioral and ultrastructural studies of desmethylmisonidazole-induced neurotoxicity in mice. *Br. J. Radiol.* **56**, 27-31.
- Griffin J. W., Price D. L., Kuethe D. O., and Golberg A. M. (1979) Neurotoxicity of misonidazole in rats: I. Neuropathology. *Neurotoxicology* **1**, 299-312.
- Klatzo I. (1967) Presidential address: Neuropathological aspects of brain edema. *J. Neuropathol. Exp. Neurol.* **26**, 1-14.
- Klatzo I. (1987) Pathophysiological aspects of brain edema. *Acta Neuropathol.* **72**, 236-239.
- Krinke G., Pericin C., Thoman P., and Hess R. (1978) Toxic encephalopathy with hippocampal lesions. *Zbl. Vet. Med. A.* **25**, 277-296.
- Lannek B. (1974) Toxicity of halogenated oxyquinolines in dogs. A clinical study. II. History, symptoms, laboratory findings, therapy, and follow-up. *Acta Vet. Scand.* **15**, 219-238.
- Lannek B. and Jönsson L. (1974) Toxicity of halogenated oxyquinolines in dogs. A clinical study. V. Pathological findings. *Acta. Vet. Scand.* **15**, 461-486.



- Olney J. W. (1980) Excitotoxic mechanisms of neurotoxicity, in *Experimental and Clinical Neurotoxicology* (Spencer P. S. and Schaumburg H. H., eds.), pp. 272-294, Williams and Wilkins, Baltimore, MD.
- Olney J. W. (1989) Excitatory amino acids and neuropsychiatric disorders. *Biol. Psychiatry* **26**, 505-525.
- O'Shaughnessy D. J. and Losos G. L. (1986) Comparison of central and peripheral nervous system lesions caused by high-dose short-term and low-dose sub-chronic acrylamide treatment in rats. *Toxicol. Pathol.* **14**, 389-394.
- Schärer K. (1972) Selective alterations of Purkinje cells in the dog after oral administration of high doses of nitroimidazole derivatives. *Verh. Dts. Ges. Pathol.* **56**, 407-410.
- Schaumburg H. H., Wisniewski H. M., and Spencer P. S. (1974) Ultrastructural studies of the dying-back process. 1. Peripheral nerve terminal and axon degeneration in systemic acrylamide intoxication. *J. Neuropathol. Exp. Neurol.* **33**, 260-284.
- Spencer P. S. and Schaumburg H. H. (1977a) Ultrastructural studies of the dying-back process. III. The evolution of experimental peripheral giant axonal degeneration. *J. Neuropathol. Exp. Neurol.* **36**, 276-299.
- Spencer P. S. and Schaumburg H. H. (1977b) Ultrastructural studies of the dying-back process. IV. Differential vulnerability of PNS and CNS fibers in experimental central-peripheral distal axonopathies. *J. Neuropathol. Exp. Neurol.* **36**, 300-320.
- Sterman A. B. and Schaumburg H. H. (1980) Neurotoxicity of selected drugs, in *Experimental and Clinical Neurotoxicology* (Spencer P. S. and Schaumburg H. H., eds.), pp. 593-612, Williams and Wilkins, Baltimore, MD.
- Tateishi J. and Otsuki S. (1975) Experimental reproduction of SMON in animals by prolonged administration of clioquinol: Clinico-pathological findings. *Japan J. Med. Sci. Biol.* **28 Suppl.**, 165-186.
- Tateishi J., Kuroda S., Ikeda H., and Otsuki S. (1975) Neurotoxicity of iodoxy-quinoline: A further study on beagle dogs. *Japan J. Med. Sci. Biol.* **28 Suppl.**, 187-195.
- Tilson H. A. (1981) The neurotoxicity of acrylamide: An overview. *Neurobehav. Toxicol. Teratol.* **3**, 445-461.
- Urtasun R. C., Chapman J. D., Feldstein M. L., Band R. P., Rabin H. R., Wilson A. F., Marynowski B., Starreveld E., and Shnitka T. (1978) Peripheral neuropathy related to misonidazole: Incidence and Pathology. *Br. J. Cancer* **37, Suppl. III**, 271-275.
- Wasserman T. H., Nelson J. S., and VonGerichten D. (1984) Neuropathy of nitroimidazole radiosensitizers: Clinical and pathological description. *Int. J. Radiat. Oncol. Biol. Phys.* **10**, 1725-1730.
- Yoshimura S., Imai K., and Ono H. (1984) Neuropathological studies in mongrel dogs administered chionoform for long term: Relationships between clinical symptoms, and changes in the spinal cord and peripheral nerves (in Japanese with English abstract), in *Annual Report of the SMON Research Commission*, pp. 80-86.

- Yoshimura S. and Imai K. (1985) Neuropathological studies in mongrel dogs administered chionoform for long term: Ultrastructural study in peripheral nerves (in Japanese with English abstract), in *Annual Report of the SMON Research Commission*, pp. 65-69.
- Yoshimura S. and Imai K. (1986) Neuropathological studies in mongrel dogs administered chionoform for long term: Examination of lumbar dorsal horns and a comparative study to the pathological lesions by 2,5-hexanedione or acrylamide (in Japanese with English abstract), in *Annual Report of the SMON Research Commission*, pp. 50-53.
- Yoshimura S., Saitoh Y., Yamaguchi H., and Imai K. (1987) Neuropathological studies in mongrel dogs administered chionoform for long term: Ultrastructural examination of spinal cord and a comparative study to the pathological lesions by 2,5-hexanedione or acrylamide (in Japanese with English abstract), in *Annual Report of the SMON Research Commission*, pp. 75-78.
- Yoshimura S., Saitoh Y., Yamaguchi H., and Imai K. (1988) Brain edema in rats caused by high dose 2,5-hexanedione treatment. *J. Toxicol. Pathol.* **1**, 165-170
- Yoshimura S., Saitoh Y., Kakimoto K., Yamaguchi H., Azegami J., Seki T., and Imai K. (1989) Neuropathological studies in beagle dogs administered chionoform or its related compounds for long-term (in Japanese with English abstract), in *Annual Report of the SMON Research Commission*, pp. 90-94.
- Yoshimura S. and Imai K. (1990) Pathological study on neurotoxicity of drugs (in Japanese with English abstract). *J. Toxicol. Pathol.* **3**, 65-89.
- Yoshimura S., Saitoh Y., Kakimoto K., Yamaguchi H., Azegami J., Seki T., and Imai K. (1990a) Ultrastructural examination in beagle dogs administered chionoform or its related compounds for long-term (in Japanese with English abstract), in *Annual Report of the SMON Research Commission*, pp. 84-87.
- Yoshimura S., Saitoh Y., Yamaguchi H., and Imai K. (1990b) Ultrastructural examination of brain edema in rats caused by high dose 2,5-hexanedione treatment. *J. Toxicol. Pathol.* **3**, 91-96.